

LETTER TO EDITOR

Deep Brain Stimulation in the Posteromedial Hypothalamic Nuclei in Refractory Aggressiveness: Post-Surgical Results of 19 Cases

Juan Carlos Benedetti-Isaac, Loida Camargo, Pascual Gargiulo, Norman López*

Medihelp Clínic, Cartagena, Colombia (Dr Benedetti-Isaac); Universidad del Sinú, Medical School, Cartagena de Indias, Colombia (Dr Camargo); Laboratorio de Neurociencias y Psicología Experimental, CONICET, Departamento de Patología, Facultad de Ciencias Médicas, Universidad Nacional de Cuyo, Mendoza, Argentina (Dr Gargiulo); Universidad de La Costa, Barranquilla, Colombia (Dr López).

Correspondence: Prof. Norman López, PhD, Universidad de La Costa, S.58 # 55 – 66, Barranquilla, Colombia (nlopez17@cuc.edu.co).

Dear Editor,

Aggression is a clinical manifestation that usually occurs in neurodevelopmental disorders. In intellectual disability, dysfunctional behavior and aggressive and maladaptive responses are common. These facts put at risk the patient's safety and cause discomfort in family members and caregivers (Gouveia et al., 2019). In general, drug prescription and behavioral therapy have favorable results in these individuals. However, there is a subset of patients who do not respond adequately to pharmacological and psychological treatment due to the severity of clinical symptoms and associated brain dysfunction (Torres et al., 2013) responsible for aggressive behavior. For this limited population of individuals, surgical interventions targeting the amygdala or hypothalamus have been proposed.

Deep brain stimulation (DBS) is a promising and novel treatment for a wide group of clinical conditions. Worldwide, the efficacy of posterior hypothalamus DBS for aggressive behavior has been significant, but only in several isolated cases (Micieli et al., 2017). For this reason, we carried out a follow-up study over 18 months to analyze the effectiveness of DBS at the level of the posteromedial hypothalamic nuclei (pHypN) in the aggressive behavior of a large cohort of patients with intellectual disability refractory to pharmacological and behavioral treatment.

A medical board analyzed the medical records of 19 patients who met the inclusion criteria (difficulties with pharmacological

and psychological treatment for 3 years; professional concept of refractoriness to treatment; significant functional impairment objectified by clinical, psychometric, and family report; medical control of other disorders and parental consent). Before the operative phase, the patients were examined by professional experts in neurosurgery, neurology, psychiatry, and neuropsychology. We used the Overt Aggression Scale (OAS) to quantify behavioral disorders degree (Silver and Yudofsky, 1991). Stereotactic implantation was then performed with the Leksell frame under general anaesthesia. It was performed using i.v. dexmedetomidine and local nerve block. Contrasting stereotactic volumetric images were acquired from computed tomography of the brain, which were fused with preoperative volumetric brain magnetic resonance imaging with gadolinium, with thin axial slices of 1 mm. Surgical planning was carried out with the help of Stealth Station Cranial Software (Medtronic, Minneapolis, USA) and Inomed software (Emmendingen, Germany). The method of Franzini et al. (2013) and Franzini et al. (2005) was used for stereotactic coordinates. Finally, the aggressiveness of patients with OAS was assessed in clinical controls at 6, 12, and 18 months. National and international ethical standards were complied with. The study was approved by the institutional ethics board (No. 087-2020).

We used repeated-measures ANOVA followed by Bonferroni post hoc to analyze the performance of patients in the OAS prior

Received: July 23, 2021; Revised: XXXX XX, XXXX; Accepted: August 25, 2021

© The Author(s) 2021. Published by Oxford University Press on behalf of CINP.

This is an Open Access article distributed under the terms of the Creative Commons Attribution-NonCommercial License (<https://creativecommons.org/licenses/by-nc/4.0/>), which permits non-commercial re-use, distribution, and reproduction in any medium, provided the original work is properly cited. For commercial re-use, please contact journals.permissions@oup.com

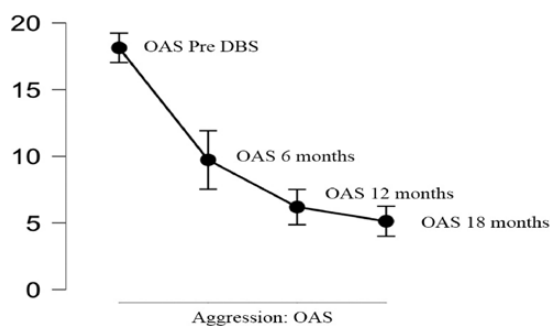


Figure 1. Variations in aggressiveness of patients after deep brain stimulation (DBS).

to DBS and in subsequent clinical controls. The effect size of the surgical intervention on the performance of the individuals in the OAS was then estimated using omega squared and Cohen d tests.

The average age of the participants was 18.4 years ($SD = 4.00$). In the neuroimaging study, the finding of cortico-subcortical atrophy was generalized. Adverse effects were reported in 1 individual due to basal ganglion hemorrhage. At the initial, pre-DBS assessment, the patients obtained high scores on the aggressiveness scale ($ME = 17.73$; $SD = 2.18$). In the post-DBS clinical controls at 6 ($ME = 9.68$; $SD = 4.02$), 12 ($ME = 5.94$; $SD = 2.27$) and 18 months ($ME = 5.1$; $SD = 1.91$), however, these values decreased. The repeated-measures ANOVA allowed us to confirm statistically significant differences in each of the moments in which the aggressiveness of the patients with the OAS was evaluated ($P < .01$) next to a high squared omega ($\omega^2 = 0.789$).

On the other hand, the post test of repeated measures showed significant intragroup changes in the mean results of the OAS before the DBS and the measurements carried out at 6 ($t = 11.27$; $P < .01$), 12 ($t = 16.52$; $P < .01$) and 18 months ($t = 17.68$; $P < .01$), with very large effect sizes ($d = 2.58$; $d = 3.78$; $d = 4.05$), respectively. Likewise between the measurement carried out at 6 months and the clinical controls at 12 ($t = 5.23$; $P < .01$) and 18 months ($t = 6.40$; $P < .01$), with sizes of large effect ($d = 1.20$; $d = 1.47$). However, between the medical control at 12 and 18 months, no differences were found in the means of the OAS ($t = 1.17$; $P > .05$).

DBS at the pHypN level in aggressive behavior refractory to pharmacological and behavioral treatment has been used in some studies with small samples. In our opinion, this is the follow-up study with the largest number of patients reported in the medical literature. In our series of cases, a clear reduction in aggressive behaviors was achieved and remained constant up to 18 months of follow-up (Figure 1), benefiting the quality of life and social inclusion of patients. Our data suggest that DBS is a successful treatment option for individuals with refractory aggression, proving to be effective and safe not only for widely known neurological disorders such as Parkinson's disease, dystonia, obsessive compulsive disorder, and essential tremor (Beszlej et al., 2019) but also in neurodevelopmental disorders, where the evidence in favor of DBS progresses at a slow pace (Ashkan et al., 2020).

We consider that rigorous protocols should be used for the selection and inclusion of patients in the clinical procedure and more frequent post-surgical controls. It may result in more secure results of the post DBS of pHyp, taking into account that some risk factors and complications with DBS may be related

to the institution where the surgery is performed (Farrokhi et al., 2020). In addition, some phenotypic characteristics of the clinical conditions of the patients may explain the secondary worsening after the application of the technique (Tsuboi et al., 2020). Finally, we suggest conducting follow-up studies longer than 18 months to confirm the time in which aggressive behavior stabilizes and flattens (Figure 1).

Acknowledgments

To the patients, their families, and the Medihelp Clinic where the procedures were performed.

Our own funds were used.

Interest Statement

None.

References

- Ashkan K, Mirza AB, Tambirajoo K, Furlanetti L (2020) Deep brain stimulation in the management of paediatric neuropsychiatric conditions: current evidence and future directions. *Eur J Paediatr Neurol* 33:146–158.
- Beszlej JA, Wieczorek T, Kobyłko A, Piotrowski P, Siwicki D, Weiser A, Fila-Witecka K, Rymaszewska J, Tabakow P (2019) Deep brain stimulation: new possibilities for the treatment of mental disorders. *Psychiatr Pol* 53:789–806.
- Farrokhi F, Buchlak QD, Sikora M, Esmaili N, Marsans M, McLeod P, Mark J, Cox E, Bennett C, Carlson J (2020) Investigating risk factors and predicting complications in deep brain stimulation surgery with machine learning algorithms. *World Neurosurg* 134:e325–e338.
- Franzini A, Marras C, Ferroli P, Bugiani O, Broggi G (2005) Stimulation of the posterior hypothalamus for medically intractable impulsive and violent behavior. *Stereotact Funct Neurosurg* 83:63–66.
- Franzini A, Broggi G, Cordella R, Dones I, Messina G (2013) Deep-brain stimulation for aggressive and disruptive behavior. *World Neurosurg* 80:S29.e11–S29.e14.
- Gouveia FV, Hamani C, Fonoff ET, Brentani H, Alho E, de Moraes RMCB, de Souza AL, Rigonatti SP, Martinez RCR (2019) Amygdala and hypothalamus: historical overview with focus on aggression. *Neurosurgery* 85:11–30.
- Micieli R, Rios AL, Aguilar RP, Posada LF, Hutchison WD (2017) Single-unit analysis of the human posterior hypothalamus and red nucleus during deep brain stimulation for aggressivity. *J Neurosurg* 126:1158–1164.
- Silver JM, Yudofsky SC (1991) The Overt Aggression Scale: overview and guiding principles. *J Neuropsychiatry Clin Neurosci* 3:S22–S29.
- Torres CV, Sola RG, Pastor J, Pedrosa M, Navas M, García-Navarrete E, Ezquiaga E, García-Camba E (2013) Long-term results of posteromedial hypothalamic deep brain stimulation for patients with resistant aggressiveness. *J Neurosurg* 119:277–287.
- Tsuboi T, Cif L, Coubes P, Ostrem JL, Romero DA, Miyagi Y, Lozano AM, De Vloo P, Haq I, Meng F, Sharma N, Ozelius LJ, Wagle Shukla A, Cauraugh JH, Foote KD, Okun MS (2020) Secondary worsening following DYT1 dystonia deep brain stimulation: a multi-country cohort. *Front Hum Neurosci* 14:242.